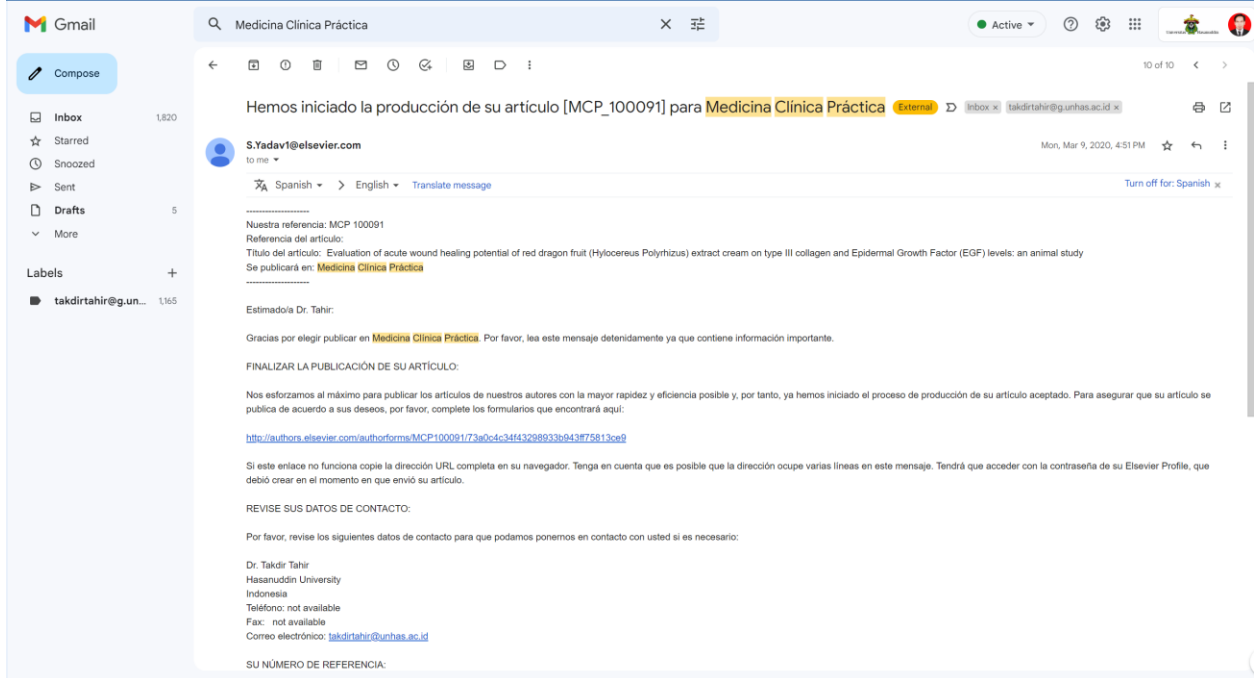
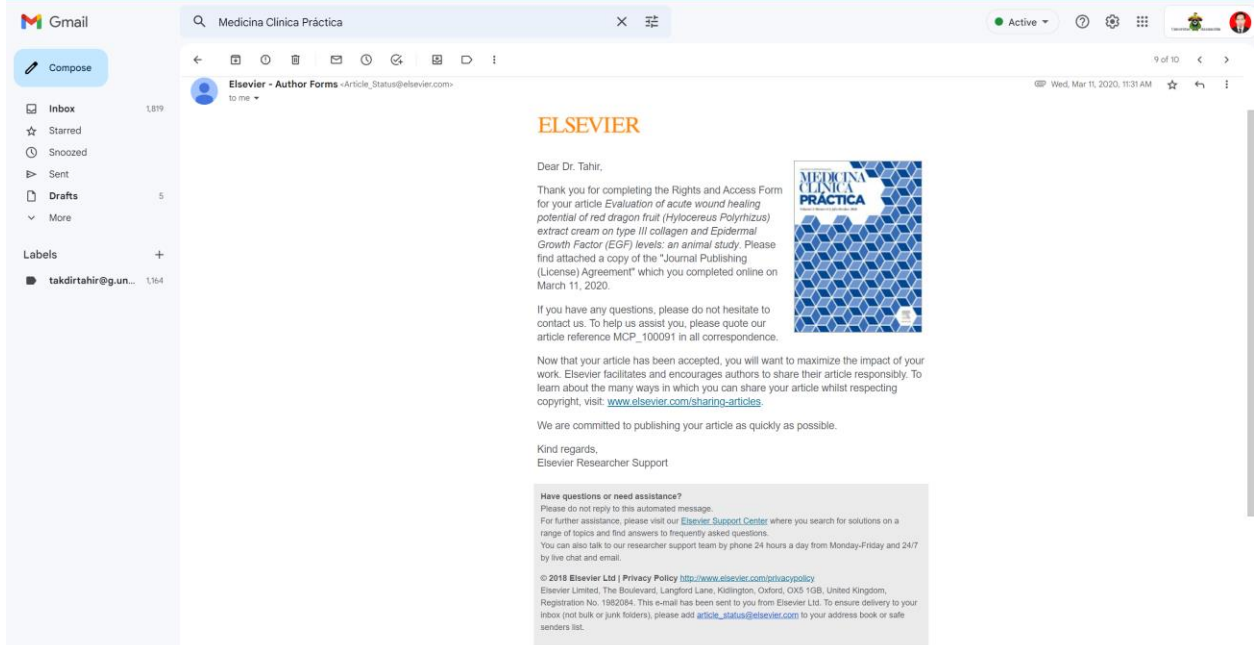


Bukti Korespondensi Dengan Jurnal Medicina Clinica Praticia 2020

1. 09 Maret 2020



2. 11 Maret 2020



3. 27 Maret 2020 (1)

The screenshot shows a Gmail interface with a search bar containing "Medicina Clínica Práctica". The email is from FERNANDEZ, PAZ (ELS-BCL) to TAKDIRTAHIR@UNHAS.AC.ID, dated Fri, Mar 27, 2020, 8:53 PM. The email body contains the following text:

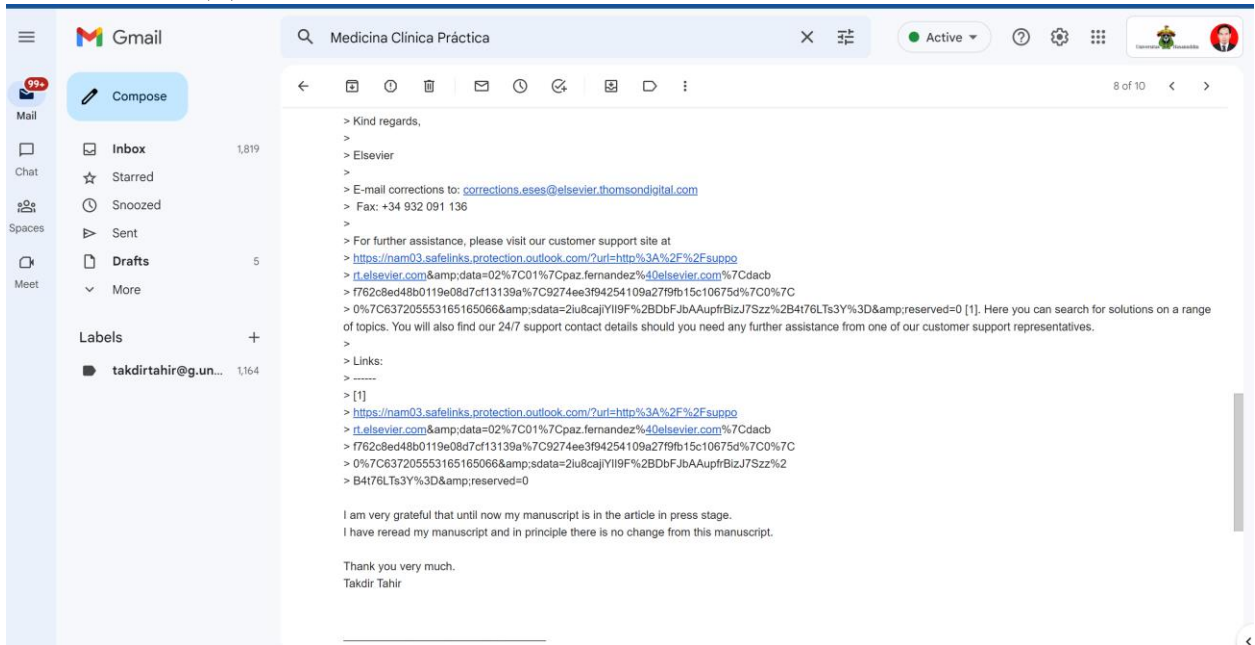
> PLEASE DO NOT ALTER THE SUBJECT LINE OF THIS E-MAIL
>
> Dear Author
>
> The proof of your article, to be published in **MEDICINA CLÍNICA**
> **PRÁCTICA**, is attached to this e-mail as a PDF file. Also attached are
> instructions on the annotation of PDF files (notas.pdf). A 'Query
> Form' is also included as the front page of the proof, detailing any
> questions regarding your article that have arisen during the
> preparation of the proof.
>
> We will do everything possible to get your article published quickly
> and accurately; to do this we need your cooperation. Please respond
> promptly (48 hours), even if you have no corrections: the sooner we
> hear from you, the sooner your corrected article will appear online.
> Please note that any delay in returning your corrections could result
> in a delay in publication and that any significant changes to the
> article as accepted for publication will only be considered at this
> stage with the permission of the Editor.
>
> Please note that proof corrections can now be annotated on-screen,
> which allows you to mark directly in the PDF file, and return the
> marked file as an e-mail attachment. See the attached instructions for
> further information.
>
> Alternative methods of returning proof corrections:
> If you do not wish to use the PDF annotations function, you may list

4. 27 Maret 2020 (2)

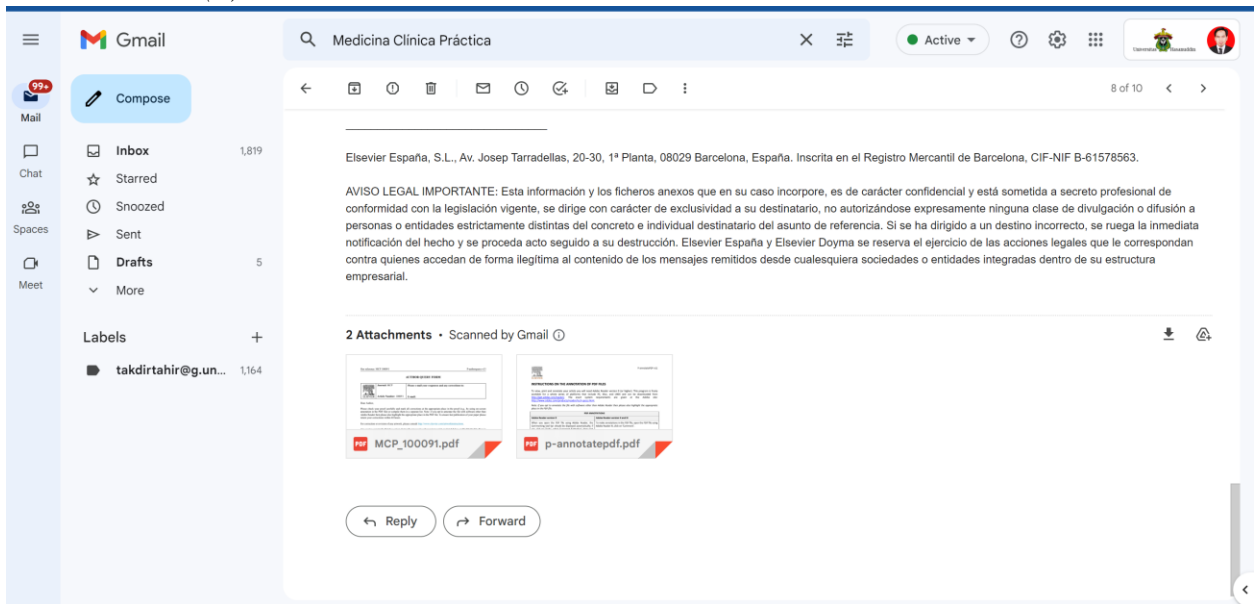
The screenshot shows the continuation of the email from FERNANDEZ, PAZ (ELS-BCL) to TAKDIRTAHIR@UNHAS.AC.ID, dated Fri, Mar 27, 2020, 8:53 PM. The email body contains the following text:

> the corrections (including replies to the Query Form) in an e-mail and
> return them to us using the 'reply' button to this e-mail. Please list
> your corrections quoting line number.
>
> If, for any reason, this is not possible, mark the corrections and any
> other comments (including replies to the Query Form) on a printout of
> your proof and fax this to the number given below, or scan the pages
> and return them by e-mail.
>
> We prefer to receive your corrections by e-mail or fax so that we can
> process your article quickly and efficiently. However, if you wish to
> return your corrections by post then please contact us and we will
> provide the full postal address.
>
> Please use this proof for checking the typesetting, editing,
> completeness and correctness of the text, tables and figures.
>
> If you submitted usable colour figures with your article they will
> appear, at no extra charge, in colour on the web if reproduced in
> colour in the attached PDF proof of your article. In the printed
> issue, colour reproduction depends on journal policy and whether or
> not you agree to bear any costs (not applicable to journals which
> appear only online). Any 'supplementary' material to your article
> (i.e., not appearing in print) will be accessible after your corrected
> article is placed online; such material is not part of the proofing
> procedure and is therefore not attached here.
>
> Before returning your proof corrections, please ensure that you have
> answered any questions raised on the Query Form and that you have
> indicated all corrections: this is the last opportunity to make
> corrections before the final publication of your article.

5. 27 Maret 2020 (3)



6. 27 Maret 2020 (4)




7. 27 Maret 2020 (Lampiran File 1: "MCP_100091.pdf")

Our reference: MCP 100091

P-authorquery-v13

AUTHOR QUERY FORM

 ELSEVIER	Journal: MCP	Please e-mail your responses and any corrections to:
	Article Number: 100091	E-mail:

Dear Author,

Please check your proof carefully and mark all corrections at the appropriate place in the proof (e.g., by using on-screen annotation in the PDF file) or compile them in a separate list. Note: if you opt to annotate the file with software other than Adobe Reader then please also highlight the appropriate place in the PDF file. To ensure fast publication of your paper please return your corrections within 48 hours.

For correction or revision of any artwork, please consult <http://www.elsevier.com/artworkinstructions>.

Any queries or remarks that have arisen during the processing of your manuscript are listed below and highlighted by flags in the proof. Click on the 'Q' link to go to the location in the proof.

Location in article	Query / Remark: click on the Q link to go Please insert your reply or correction at the corresponding line in the proof
Q1	<p>Please confirm that given name and surname are correctly identified. The different colors indicate whether tagged as first or last name. Please note that proper identification is key for correct indexing of the article.</p> <div style="border: 1px solid black; padding: 5px; margin-top: 10px;"><p>Please check this box or indicate your approval if you have no corrections to make to the PDF file <input type="checkbox"/></p></div>

Thank you for your assistance.



Original article

1 Evaluation of acute wound healing potential of red dragon fruit
2 (*Hylocereus Polyrhizus*) extract cream on type III collagen and
3 Epidermal Growth Factor (EGF) levels: An animal study

4 Q1 Takdir Tahir^{a,*}, Nur Febrianti^b, Sri Wahyuni^c, Rabia^d, Yuliana Syam^e

5 ^a Department of Medical-Surgical Nursing, Faculty of Nursing, Hasanuddin University, Indonesia

6 ^b Department of Medical-Surgical Nursing, School of Nursing Graha Edukasi, Indonesia

7 ^c Department of Medical-Surgical Nursing, School of Nursing Nani Hasanuddin, Indonesia

8 ^d Department of Physiotherapy, Faculty of Nursing, Hasanuddin University, Indonesia

9 ^e Department of Basic Nursing, Faculty of Nursing, Hasanuddin University, Indonesia

11 article info

12 Article history:

13 Received 29 May 2019

14 Accepted 15 July 2019

15 Available online xxx

16 Keywords:

17 Hylocereus Polyrhizus

18 Type III collagen

19 EGF

20 Wound healing

11 abstract

12 **Objective:** To evaluate the acute wound healing potential of RDFE cream on type III collagen and EGF levels.

13 **Method:** Male Albino Wistar rats have randomly divided into three groups: negative control received base cream, positive control administered with 10% zalfpovidone and RDFE group was treated with RDFE cream. The healing effects were assessed on EGF, type III collagen, wound diameter, tissue granulation, and epithelization, for 3, 7, 11, and 14 days post-treatment.

14 **Results:** On the 3rd-day post-treatment, the greatest reduction in wound diameters were shown significantly in the positive control among groups ($p < 0.05$). Although the data were statistically insignificant, RDFE groups showed the highest level of type III collagen among groups after 7-day treatment ($p > 0.05$).

15 **Conclusion:** The effect of RDFE cream in the wound healing process on type III collagen appeared on day 7. However, an increase of EGF levels was not observed following RDFE treatment.

16 © 2020 The Authors. Published by Elsevier España, S.L.U. This is an open access article under the CC BY-NC-ND license (<http://creativecommons.org/licenses/by-nc-nd/4.0/>).

23 Introduction

24 Globally, more than 305 million acute wounds are recorded
25 per year. The number of the recorded acute wound is more
26 than nine times of the total number of people around the world
27 living with cancer.¹ Thus, treatment approaches are urgently
28 needed to overcome the high number of acute wounds. Vari-
29 ous attempts are used to accelerate the wound healing process.
30 However alternative/complementary using natural compounds are
31 highly demanded.² Also, the topical application of medication is
32 preferred due to the lack of adverse effect on other organs.³

33 Plants are the greatest sources of new compounds which have
34 properties including antimicrobial, antiviral, antioxidants, and the
35 others. According to WHO, the properties of plants provide a way

36 to combat diseases.³ Red dragon fruit is one of the fruits which
37 was grown in Indonesia. The natural ingredients contained in the
38 Red Dragon Fruit have potential in the wound healing process. In
39 Indonesia, the effect of red dragon fruit extract (RDFE) on wound
40 healing has been explored in the last three years.⁴

41 The healing process of wounds is an interaction of cellular
42 structure reconstruction and multiple coordinated cascades of
43 cellular and molecular events, which leads to tissue repair.⁵ The
44 interaction of cytokines, which have mitogenic, pro-inflammatory
45 and anti-inflammatory activities, and proteases, are playing a role
46 in each stage of the healing process.⁵ EGF is one of the growth
47 factors which plays a main role in the epithelialization process.⁶
48 Collagen also plays an important role in the proliferation process.
49 It is secreted to the extracellular space in the form of pro-collagen
50 and then cleaved from the tropocollagen.⁷ This tropocollagen
51 forms a strong cross bond, making collagen fibers resistant to
52 damage. And the more these cross-links form in intramolecular
53 and intermolecular collagen, the stronger the wound healing
54 becomes.⁸ The importance of the role of EGF and collagen make
55 those become the sensitive biomarker of the wound healing
56 process. Although many studies have been conducted on RDFE,

Peer-review under responsibility of the scientific committee of the International Conference on Women and Societal Perspective on Quality of Life (WOSQUAL-2019). Full-text and the content of it is under responsibility of authors of the article.

* Corresponding author.
E-mail address: takdir@umhas.ac.id (T. Tahir).

<https://doi.org/10.1016/j.mcsp.2020.100091>

2603-9249/© 2020 The Authors. Published by Elsevier España, S.L.U. This is an open access article under the CC BY-NC-ND license (<http://creativecommons.org/licenses/by-nc-nd/4.0/>).

Please cite this article in press as: Tahir T, et al. Evaluation of acute wound healing potential of red dragon fruit (*Hylocereus Polyrhizus*) extract cream on type III collagen and Epidermal Growth Factor (EGF) levels: An animal study. Med Clin Pract. 2020. <https://doi.org/10.1016/j.mcsp.2020.100091>

its potential effects on EGF and collagen have not been explored yet. Therefore, this study aimed to evaluate the wound healing potential of RDFE cream on EGF and type III collagen levels.

Method

Seventy two healthy albino male Wistar rats aged 6–8 weeks weighing 250–350 g were obtained from Gajah Mada University, Yogyakarta, Indonesia, then were randomly divided into 3 groups: (1) the positive control group ($n = 24$) administered with 2-mg 10% povidone-iodine cream, (2) the negative control group received 2-mg base cream, and (3) RDFE group was treated with 2-mg RDFE cream. Afterward, each group was divided into four subgroups of 6 animals supervised for 3, 7, 11, and 14 days post-treatments. The experimental procedures were performed with the approval of The Research Ethics Committee of the Faculty of Medicine, Hasanuddin University (No 400/H4.8.4.5.31/PP36-COMETIC/2018).

The rats were anesthetized by inhalation using isoflurane (0.01–0.05 $\mu\text{g}/\text{kg}$) before wound infliction.⁹ The excision area (left and right back) were firstly shaved using a hair remover (Jollen) and cleaned with chlorhexidine 0.5% + alcohol 70%.⁹ The wound was made with a biopsy punch of 8 mm in diameter.¹⁰ The protocol of this study refers to the Council for International Organizations of Medical Sciences (CIOMS).¹¹

The red dragon fruits were purchased from the plantation in Samarinda, East Kalimantan, Indonesia. The fruits were extracted using methanol, then the percentage of free radical inhibition (DPPH) test was conducted. The anti-free radical activity of RDFE and vitamin C obtained IC_{50} values, respectively 314.69 ppm, and 3.28 ppm. Every 1 gram of RDFE contains 1062 GAE of polyphenols and 8.3 mg flavonoid. 7.5% concentration of RDFE were used to make the topical RDFE cream.

On the 3rd, 7th, 11th, and 14th day, the measurement of wound diameter were performed using a slide/wound ruler. On the respective days, skin tissue fragments containing the wound with a margin of 1 cm were collected. Those withdrawn from the left-back were fixed in 10% normal formalin buffer solution for further histopathological assessment, while those from the right-back were immediately stored in 0.9% NaCl buffer for further ELISA analysis.

The skin samples fixed in 10% normal formalin buffer solution, were dehydrated with various concentrations of alcohol (70%, 80%, 90%, and absolute alcohols I and II), cleared by xylol and embedded in paraffin. The tissues were put into a liquid paraffin printer and left until the paraffin hardens. The tissues then were cut into 5- μm -thick sections using a microtome. The tissue sections were rehydrated and stained with hematoxylin–eosin (HE). The tissue granulation thickness (proliferation) and connective tissue area were measured using a JVC, Japan micrometer with four times magnification. The epithelial scores and tissue granulation thickness were evaluated. The semi-quantitative method of histological sections was used to assess the epithelization of the wound.¹² Meanwhile, the thickness of tissue granulation was assessed using the histological score, in which the score of 1 (thin), score of 2 (moderate), and a score of 3 (thick) are used.¹³

The skin fragments were homogenized with sonicator, and supernatants were collected. Quantitative measurements of EGF levels was performed using a commercial enzyme-linked immunosorbent assay (ELISA) kit (EGF mouse kit Immunoassay Quantikine kit; MEG00) according to the manufacturer's instructions. Meanwhile, type III collagen levels were measured using ELISA kit (Mouse Collagen III; E0338, Shanghai, China) according to the manufacturer's instructions.

One-way analysis of variance (ANOVA) and Kruskal–Wallis tests was carried out to identify the different effects between treated groups and control groups using SPSS Ver.21 (SPSS Inc., Chicago, IL, USA).

Results

On day 3, the smallest wound diameters were shown significantly in the positive control among groups ($p < 0.05$). After seven days of treatment, the RDFE group showed the smallest diameter among groups, although the data were statistically insignificant ($p > 0.05$). Meanwhile, on day 11 after treatment, the smallest diameter of the wound was shown in the negative control among groups (Table 1), but the differences were not statistically significant ($p > 0.05$). On day 14, the positive control showed the smallest diameter of wound among groups, but no statistical significance was found ($p > 0.05$). The macroscopic descriptions of wound diameter reduction were presented in Fig. 1. Positive control groups indicated the thinner granulation tissue on day 14 compared to other groups. In the re-epithelialization tissue, the epithelial closure appeared better on positive control group among groups on day 14 (Fig. 2).

After 3-day treatment, type III collagen levels were found lower in the RDFE group compared to other groups, but the differences were statistically insignificant ($p > 0.05$). RDFE groups showed the highest level of type III collagen compared to another group after 7-day treatment ($p > 0.05$). However, after 11 and 14-day treatment, the highest levels of type III collagen were shown in positive control groups, as shown in Table 2.

After cream treatment for three days, the clinical EGF levels were highest in positive controls, compared to the negative controls and RDFE groups. However, no statistical significance was found ($p > 0.05$). On day 7 and 11 after treatment, RDFE groups showed the highest level of EGF compared to positive and negative controls, although the differences were not statistically significant. Finally, on day 14, after treatment, the EGF levels were shown higher in positive controls, compared to RDFE and negative controls, as shown in Table 3.

Discussion

Our study is the first study that examines the potential effect of RDFE on acute wound healing in healthy subjects. The main findings of the present study were that the significant wound diameter reduction was observed on day three post-treatment, while on the 7th day, the peak effects of RDFE were shown on wound diameter compared to other groups. However, on the 14th day, greater reduction in wound diameter appeared in RDFE group, compared to

Table 1
Wound diameter evaluation in the different treatment group.

Group	Day 3			Day 7			Day 11			Day 14		
	n	Mean \pm SD (mm)	p	n	Mean \pm SD (mm)	p	n	Mean \pm SD (mm)	p	n	Mean \pm SD (mm)	p
Negative Controls	5	8.40 \pm 0.89	0.03*	5	6.20 \pm 1.48	0.47	5	4 \pm 1	0.89	5	1.80 \pm 1.30	0.41
Positive Controls	6	6.67 \pm 1.21		6	5.33 \pm 1.37		4	4.25 \pm 0.5		5	0.8 \pm 1.30	
RDFE	6	8 \pm 0.89		6	5.17 \pm 1.47		5	4.40 \pm 2.07		4	1.25 \pm 0.5	

RDFE: Red Dragon Fruit Extracts. Asterisk (*) indicates significantly different $p < 0.05$ as compared to negative controls and RDFE groups.

Please cite this article in press as: Tahir T, et al. Evaluation of acute wound healing potential of red dragon fruit (*Hylocereus Polyrhizus*) extract cream on type III collagen and Epidermal Growth Factor (EGF) levels: An animal study. Med Clin Pract. 2020. <https://doi.org/10.1016/j.mcsp.2020.100091>

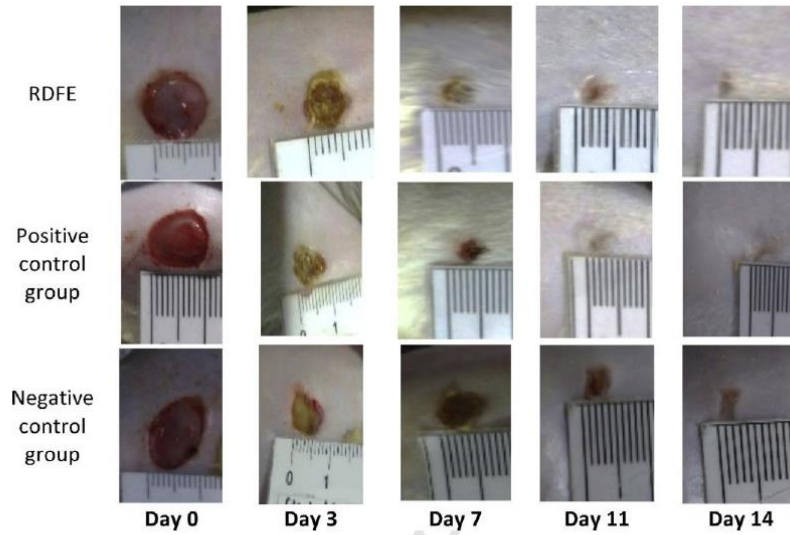


Fig. 1. Macroscopic analysis of wound diameter in the different treatment group.

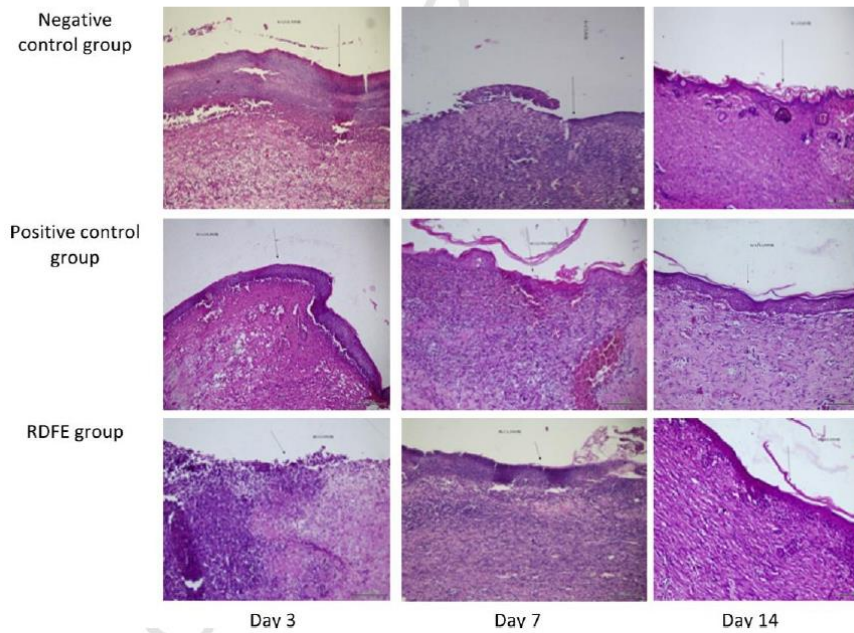


Fig. 2. Representative images of histological sections of the three experimental groups.

Table 2
The Effect of RDFE cream on type III collagen levels.

Group	Day 3			Day 7			Day 11			Day 14		
	n	Mean ± SD (ng/mL)	P	n	Mean ± SD (ng/mL)	p	n	Mean ± SD (ng/mL)	p	N	Mean ± SD (ng/mL)	p
Negative Control	5	6.62 ± 0.92	0.520	5	6.77 ± 1.32	0.095	5	8.60 ± 0.78	0.191	5	7.93 ± 0.44	0.213
Positive Control	6	6.22 ± 0.95		6	7.16 ± 1.01		4	9.19 ± 0.59		5	8.65 ± 0.97	
RDFE	6	5.67 ± 1.89		6	8.35 ± 1.20		5	8.34 ± 0.55		4	7.95 ± 0.37	

RDFE: Red Dragon Fruit Extracts.

Please cite this article in press as: Tahir T, et al. Evaluation of acute wound healing potential of red dragon fruit (*Hylocereus Polyrhizus*) extract cream on type III collagen and Epidermal Growth Factor (EGF) levels: An animal study. Med Clin Pract. 2020. <https://doi.org/10.1016/j.mcsp.2020.100091>

Table 3
The Effect of RDFE cream on EGF levels.

Group	Day 3			Day 7			Day 11			Day 14		
	n	Median (Min–Max) (ng/L)	p	n	Median (Min–Max) (ng/L)	p	n	Median (Min–Max) (ng/L)	p	n	Median (Min–Max) (ng/L)	p
Negative control	5	110.74 (104.27–162.49)	0.25	5	109.63 (108.95–160.11)	0.08	5	159.08 (152.19–164.87)	0.67	5	153.98 (123.17–182.75)	0.96
Positive control	6	138.32 (100.61–156.53)		6	152.79 (148.02–168.53)		4	162.70 (157.30–174.32)		5	157.55 (145.98–164.53)	
RDFE	6	102.61 (96.44–167.68)		6	169.38 (129.98–176.96)		5	163.34 (131.93–164.34)		4	156.61 (148.28–162.15)	

RDFE: Red Dragon Fruit Extracts.

162 other groups. The reduction of wound diameter might result from
163 the presence of flavonoids and phenol as anti-inflammatory com-
164 ponents in RDFE. RDF also contains quercetin and tannin, which
165 play a role in the wound healing process.¹⁴ A study conducted
166 by Kant et al. (2017) revealed that the topical application of 0.1%
167 quercetin accelerates the closure of wound compared to the nega-
168 tive control.¹⁵ We assume the quercetin in RDFE cream contributes
169 to wound closure through promoting the angiogenesis and prolif-
170 eration of epithelial cell and fibroblast.¹⁵

171 The present study showed that RDFE cream containing flavonoid
172 contributed to increasing the production of type III collagen. The
173 highest peak of type III collagen levels was observed on day seven
174 post RDFE treatment, although the difference between groups was
175 statistically insignificant. During the initial wound healing, type III
176 collagen is the main collagen produced by fibroblasts in granulation
177 tissue during the proliferation phase. It firstly appears after 48–72 h
178 and is maximally secreted between 5 and seven days.¹⁶ The num-
179 ber of collagen was increased at the beginning of the repair phase,
180 reaching a maximum between 2 and 3 weeks after injury.¹⁷ Many
181 studies using natural ingredients containing flavonoids have been
182 shown to increase collagen synthesis in wound healing. Therefore
183 we assume the content of flavonoids in RDFE cream might contrib-
184 ute to the process of wound healing through an increase of
185 collagen synthesis.

186 Our study found that there were no statistically differences in
187 EGF level between groups. Our finding was not by the findings of
188 the previous studies evaluating the growth factors. Djamiluddin
189 (2016) indicated the elevation of FGF levels in RDFE group in wound
190 proliferation phase.¹⁸ There are several studies on cytokines that
191 play a role in the wound healing process, for instance, MMP-9 levels
192 after 14 days of treatment were shown to decrease in the topical
193 RDFE group.¹⁹ The other findings revealed that IL-6 levels in the
194 RDFE group were lower compared to the group treated with
195 base cream.²⁰ RDF was also reported to contain vitamin E.²¹ Butt
196 et al. (2017) who examined in vitro human dermal fibroblasts indi-
197 cated vitamin E induced a significant increase in paracrine release
198 of EGF.²² The different findings in several studies might result from
199 differences in the type of RDFE, type of Wistar, body weight, age, and
200 time of wound measurement. We also assumed that the vitamin E
201 content in RDFE cream might be insufficient to induce a significant
202 increase in EGF levels.

203 Conclusions

204 The wound healing potential effect of RDFE cream on type III
205 collagen was appeared on day 7. However, an increase of EGF lev-
206 els was not observed following RDFE treatment. Therefore, further
207 researches on a higher concentration of RDFE are needed to inves-
208 tigate the optimal concentrations of RDFE, which can induce the
209 optimal wound healing.

Conflict of interests

The authors declare that they have no conflict of interests regarding the publication of this paper.

Acknowledgments

Authors would like to thank the Animal Laboratory, Anatomical Pathology Laboratory of Hasanuddin University and Indonesian Muslim University.

References

1. Wound Care Stats. Swift Medical Inc. Available from: <https://swiftmedical.com/>.
2. Tam WS, Arulseivan P, Ng S-F, Mat Taib CN, Sarian MN, Fakurazi S. Improvement of diabetic wound healing by topical application of Vicenin-2 hydrocolloid film on Sprague Dawley rats. *BMC Complement Altern Med* 2019;19:20. <http://dx.doi.org/10.1186/s12906-018-2427-y>.
3. Lopes CML, Baratella-Evêncio L, Souza IA, Oliveira EB, Sá JGA, Santana MAN, et al. Evaluation of cytotoxicity and wound healing activity of *Avicennia schaueriana* in cream. *An Acad Bras Cienc* 2019;91:e20180171.
4. Tahir T, Bakri S, Patellongi I, Aman M, Miskad UA, Maryunis M, et al. Evaluation of topical red dragon fruit extract effect (*Hylocereus polyrhizus*) on tissue granulation and epithelialization in diabetes mellitus (DM) and non-DM wistar rats: pre-eliminary study. *IJSEBAR* 2017;3:2:309–20.
5. Lobmann R, Schultz G, Lehnert H. Proteases and the diabetic foot syndrome: mechanisms and therapeutic implications. *Diabetes Care* 2005;28:461–71.
6. Peplow PV, Chatterjee MP. A review of the influence of growth factors and cytokines in *in vitro* human keratinocyte migration. *Cytokine* 2013;62:1–21. <http://dx.doi.org/10.1016/j.cyt.2013.02.015>.
7. Prockop D, Sieron AL, Li S. Procollagen N-proteinase and procollagen C-proteinase: two unusual metalloproteinases that are essential for procollagen processing probably have important roles in development and cell signaling. *Matrix Biol* 1998;16:399–408.
8. Qing C. The molecular biology in wound healing and non-healing wound. *Chin J Traumatol* 2017;20:189–93. <http://dx.doi.org/10.1016/j.cjtee.2017.06.001>.
9. Masoko P, Picard J, Eloff JN. The use of a rat model to evaluate the *in vivo* toxicity and wound healing activity of selected combretum and terminalia (combretaceae) species extracts. *Onderstepoort J Vert* 2010;77:1–7. <http://dx.doi.org/10.4102/ojvr.v77n1.2>.
10. Prestes MA, Ribas CA, Ribas Filho JM, Moreira LB, Boldt AB, Brustolin EV, et al. Wound healing using ionic silver dressing and nanocrystalline silver dressing in rats. *Acta Cir Bras* 2012;27:761–7.
11. Council for International Organizations of Medical Sciences. International Ethical Guidelines for Health-related research involving humans. Geneva: Council for International Organizations of Medical Sciences (CIOMS); 2016.
12. Gal P, Kilik R, Mokry M, Vidimsky B, Vasilenko T, Mozes S, et al. Simple method of open skin wound healing model in corticosteroid-treated and diabetic rats: standardization of semi-quantitative and quantitative histological assessments. *Vet Med* 2008;53:652–9.
13. Perini JA, Angeli-Gamba T, Alessandra-Perini J, Ferreira LC, Nasciutti LE, Machado DE. Topical application of Acheflan on rat skin injury accelerates wound healing: a histopathological, immunohistochemical and biochemical study. *BMC Complement Altern Med* 2015;15:203.
14. Gopalakrishnan A, Ram M, Kumawat S, Tandan S, Kumar D. Quercetin accelerated cutaneous wound healing in rats by increasing levels of VEGF and TGF- β 1. *Indian J Exp Biol* 2016;54:187–95.
15. Kant V, Jangir BL, Nigam A, Kumar V, Sharma S. Dose regulated cutaneous wound healing potential of quercetin in male rats. *Biochem Pharmacol* 2017;19:82–7.
16. Upadhyay A, Chattopadhyay P, Goyary D, Mazumder PM, Veer V. *Iskra coccinea* enhances cutaneous wound healing by upregulating the expression of

Please cite this article in press as: Tahir T, et al. Evaluation of acute wound healing potential of red dragon fruit (*Hylocereus Polyrhizus*) extract cream on type III collagen and Epidermal Growth Factor (EGF) levels: An animal study. *Med Clin Pract*. 2020. <https://doi.org/10.1016/j.mcsp.2020.100091>

- 267 collagen and basic fibroblast growth factor. *Int Schol Res Pharmacol* 2014;2014: 268 9-13.
- 269 17. Li J, Chen J, Kirsner R. Pathophysiology of acute wound healing. *Clin Dermatol* 270 2007;25:9-18.
- 271 18. Djalaluddin N. *Efek pemberian topikal ekstrak buah naga merah (Hylocereus* 272 *polyrhizus) terhadap perubahan Fibroblast Growth Factor (FGF) dan diameter luka* 273 *pada wistar*. Universitas Hasanuddin; 2016.
- 274 19. Mas'ud A. *Pengaruh pemberian ekstrak buah naga merah topikal pada luka akut* 275 *terhadap perubahan kadar Matrix Metalloproteinase-9 (MMP-9) pada wistar*. Uni-
versitas hasanuddin; 2017.
20. Thalib A. *Pengaruh pemberian krim topikal ekstrak buah naga merah (hylocereus* 276 *polyrhizus) pada luka akut terhadap kadar interleukin-6 fase inflamasi pada wistar.* 277 *Universitas Hasanuddin*; 2017.
- 278 21. Khalili MA, Norhayati, Rokiah, Asmah, Muskinah S, Manaf A. Determination of 279 radical scavenging activity and Vitamin A, C and E in organically grown Red 280 Pitaya (*Hylocereus* sp.). *Int Food Res J* 2010;17:405-9.
- 281 22. Butt H, Mehmood A, Ali M, Tasneem S, Anjum MS, Tarar MN, et al. Protective 282 role of vitamin E preconditioning of human dermal fibroblasts against thermal 283 stress in vitro. *Life Sci* 2017;184:1-9.
- 284

UNCORRECTED PROOF


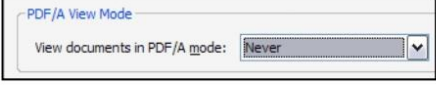

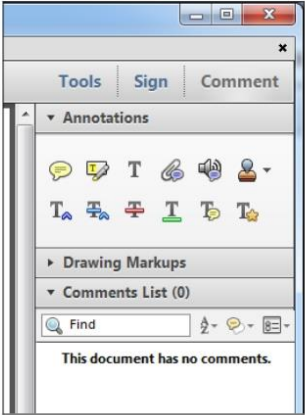
8. 27 Maret 2020 (Lampiran File 2: “p-annotatpdf.pdf”)





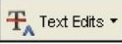





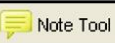



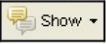
INSTRUCTIONS ON THE ANNOTATION OF PDF FILES

To view, print and annotate your article you will need Adobe Reader version 9 (or higher). This program is freely available for a whole series of platforms that include PC, Mac, and UNIX and can be downloaded from <http://get.adobe.com/reader/>. The exact system requirements are given at the Adobe site: <http://www.adobe.com/products/reader/tech-specs.html>.

Note: if you opt to annotate the file with software other than Adobe Reader then please also highlight the appropriate place in the PDF file.

PDF ANNOTATIONS	
<p>Adobe Reader version 9</p> <p>When you open the PDF file using Adobe Reader, the Commenting tool bar should be displayed automatically; if not, click on 'Tools', select 'Comment & Markup', then click on 'Show Comment & Markup tool bar' (or 'Show Commenting bar' on the Mac). If these options are not available in your Adobe Reader menus then it is possible that your Adobe Acrobat version is lower than 9 or the PDF has not been prepared properly.</p>  <p>(Mac)</p> <p>PDF ANNOTATIONS (Adobe Reader version 9)</p> <p>The default for the Commenting tool bar is set to 'off' in version 9. To change this setting select 'Edit Preferences', then 'Documents' (at left under 'Categories'), then select the option 'Never' for 'PDF/A View Mode'.</p>  <p>(Changing the default setting, Adobe version 9)</p>	<p>Adobe Reader version X and XI</p> <p>To make annotations in the PDF file, open the PDF file using Adobe Reader XI, click on 'Comment'.</p> <p>If this option is not available in your Adobe Reader menus then it is possible that your Adobe Acrobat version is lower than XI or the PDF has not been prepared properly.</p>  <p>This opens a task pane and, below that, a list of all Comments in the text. These comments initially show all the changes made by our copyeditor to your file.</p> 

HOW TO...		
Action	Adobe Reader version 9	Adobe Reader version X and XI
Insert text	Click the 'Text Edits' button  on the Commenting tool bar. Click to set the cursor location in the text and simply start typing. The text will appear in a commenting box. You may also cut-and-paste text from another file into the commenting box. Close the box by clicking on 'X' in the top right-hand corner.	Click the 'Insert Text' icon  on the Comment tool bar. Click to set the cursor location in the text and simply start typing. The text will appear in a commenting box. You may also cut-and-paste text from another file into the commenting box. Close the box by clicking on 'X' in the top right-hand corner.
Replace text	Click the 'Text Edits' button  on the Commenting tool bar. To highlight the text to be replaced, click and drag the cursor over the text. Then simply type in the replacement text. The replacement text will appear in a commenting box. You may also cut-and-paste text from another file into this box. To replace formatted text (an equation for example) please Attach a file (see below).	Click the 'Replace (Ins)' icon  on the Comment tool bar. To highlight the text to be replaced, click and drag the cursor over the text. Then simply type in the replacement text. The replacement text will appear in a commenting box. You may also cut-and-paste text from another file into this box. To replace formatted text (an equation for example) please Attach a file (see below).
Remove text	Click the 'Text Edits' button  on the Commenting tool bar. Click and drag over the text to be deleted. Then press the delete button on your keyboard. The text to be deleted will then be struck through.	Click the 'Strikethrough (Del)' icon  on the Comment tool bar. Click and drag over the text to be deleted. Then press the delete button on your keyboard. The text to be deleted will then be struck through.
Highlight text/ make a comment	Click on the 'Highlight' button  on the Commenting tool bar. Click and drag over the text. To make a comment, double click on the highlighted text and simply start typing.	Click on the 'Highlight Text' icon  on the Comment tool bar. Click and drag over the text. To make a comment, double click on the highlighted text and simply start typing.
Attach a file	Click on the 'Attach a File' button  on the Commenting tool bar. Click on the figure, table or formatted text to be replaced. A window will automatically open allowing you to attach the file. To make a comment, go to 'General' in the 'Properties' window, and then 'Description'. A graphic will appear in the PDF file indicating the insertion of a file.	Click on the 'Attach File' icon  on the Comment tool bar. Click on the figure, table or formatted text to be replaced. A window will automatically open allowing you to attach the file. A graphic will appear indicating the insertion of a file.
Leave a note/ comment	Click on the 'Note Tool' button  on the Commenting tool bar. Click to set the location of the note on the document and simply start typing. <u>Do not use this feature to make text edits.</u>	Click on the 'Add Sticky Note' icon  on the Comment tool bar. Click to set the location of the note on the document and simply start typing. <u>Do not use this feature to make text edits.</u>

HOW TO...		
Action	Adobe Reader version 9	Adobe Reader version X and XI
Review	To review your changes, click on the 'Show' button  on the Commenting tool bar. Choose 'Show Comments List'. Navigate by clicking on a correction in the list. Alternatively, double click on any mark-up to open the commenting box.	Your changes will appear automatically in a list below the Comment tool bar. Navigate by clicking on a correction in the list. Alternatively, double click on any mark-up to open the commenting box.
Undo/delete change	To undo any changes made, use the right click button on your mouse (for PCs, Ctrl-Click for the Mac). Alternatively click on 'Edit' in the main Adobe menu and then 'Undo'. You can also delete edits using the right click (Ctrl-click on the Mac) and selecting 'Delete'.	To undo any changes made, use the right click button on your mouse (for PCs, Ctrl-Click for the Mac). Alternatively click on 'Edit' in the main Adobe menu and then 'Undo'. You can also delete edits using the right click (Ctrl-click on the Mac) and selecting 'Delete'.

SEND YOUR ANNOTATED PDF FILE BACK TO ELSEVIER

Save the annotations to your file and return as instructed by Elsevier. Before returning, please ensure you have answered any questions raised on the Query Form and that you have inserted all corrections: later inclusion of any subsequent corrections cannot be guaranteed.

FURTHER POINTS

- Any (grey) halftones (photographs, micrographs, etc.) are best viewed on screen, for which they are optimized, and your local printer may not be able to output the greys correctly.
- If the PDF files contain colour images, and if you do have a local colour printer available, then it will be likely that you will not be able to correctly reproduce the colours on it, as local variations can occur.
- If you print the PDF file attached, and notice some 'non-standard' output, please check if the problem is also present on screen. If the correct printer driver for your printer is not installed on your PC, the printed output will be distorted.

9. 31 Maret 2020 (1)

Gmail Medicina Clínica Práctica

Compose

Inbox 1,821
Starred
Snoozed
Sent
Drafts 5
More
Labels +
takdirtahir@g.un... 1,166

Search: Medicina Clínica Práctica

Active

7 of 10

From: paz.fernandez@elsevier.com
To: me
Date: Mar 31, 2020, 8:02 AM

Spanish > English Translate message Turn off for: Spanish

POR FAVOR, NO MODIFIQUE EL TEXTO DEL ASUNTO DE ESTE MENSAJE

Nuestra referencia: MCP 100091
Referencia del artículo:
Título del artículo: Evaluation of acute wound healing potential of red dragon fruit (*Hylocereus Polyrhizus*) extract cream on type III collagen and Epidermal Growth Factor (EGF) levels: an animal study
Se publicará en: [Medicina Clínica Práctica](#)

Estimado/a Dr. Tahir:

Recientemente le enviamos las pruebas del artículo mencionado arriba. Nuestros registros indican que todavía no hemos recibido sus correcciones o su aprobación para publicarlo sin cambios. Por favor, avisenos lo antes posible si no ha recibido las pruebas de su artículo.

Si todavía no lo ha hecho, por favor, envíenos sus correcciones o su aprobación para publicar el artículo lo antes posible (puede enviarnos solo las páginas que contengan correcciones).

Las pruebas deben ser utilizadas únicamente para revisar la composición tipográfica, la edición, la integridad y la exactitud de los textos, las tablas y las figuras.

Si usted ya ha devuelto sus correcciones en las últimas 48 horas, por favor, ignore este mensaje.

Tenga en cuenta que una vez recibamos sus correcciones, su artículo se considerará finalizado y ya no se podrán realizar más cambios.

Muchas gracias por su colaboración. Por favor, póngase en contacto con nosotros si tiene alguna consulta e incluya siempre la referencia de su artículo (MCP 100091).

Atentamente,
Sra. Paz Fernandez
Elsevier

10. 31 Maret 2020 (2)

Gmail Medicina Clínica Práctica

Compose

Inbox 1,821
Starred
Snoozed
Sent
Drafts 5
More
Labels +
takdirtahir@g.un... 1,166

Search: Medicina Clínica Práctica

Active

7 of 10

Muchas gracias por su colaboración. Por favor, póngase en contacto con nosotros si tiene alguna consulta e incluya siempre la referencia de su artículo (MCP 100091).

Atentamente,
Sra. Paz Fernandez
Elsevier
Correo electrónico: paz.fernandez@elsevier.com

¿TIENE ALGUNA PREGUNTA O NECESITA AYUDA?

Para obtener más ayuda, visite nuestra página de Customer Support, donde puede buscar soluciones a una gran variedad de temas y encontrar respuesta a las preguntas más frecuentes (página web en inglés con una selección de artículos en español). También puede contactar con nuestro equipo de Atención al Cliente por teléfono o por correo electrónico (en español: de lunes a viernes de 09:00 a 17:00 GMT, en inglés: de lunes a viernes, las 24 horas) y 24/7 a través del chat en vivo (solo en inglés).

Puede empezar aquí (página web en inglés): <http://service.elsevier.com/get/home/supporthub/publishing>

Copyright © 2018 Elsevier B.V. | Privacy Policy <http://www.elsevier.com/privacypolicy>
Elsevier Limited, The Boulevard, Langford Lane, Kidlington, Oxford, OX5 1GB, United Kingdom, Registration No. 1982084

Elsevier España, S.L., Av. Josep Tarradellas, 20-30, 1ª Planta, 08029 Barcelona, España. Inscrita en el Registro Mercantil de Barcelona, CIF-NIF B-61578563.

AVISO LEGAL IMPORTANTE: Esta información y los ficheros anexos que en su caso incorpore, es de carácter confidencial y está sometida a secreto profesional de conformidad con la legislación vigente, se dirige con carácter de exclusividad a su destinatario, no autorizándose expresamente ninguna clase de divulgación o difusión a personas o entidades estrictamente distintas del concreto e individual destinatario del asunto de referencia. Si se ha dirigido a un destino incorrecto, se ruega la inmediata notificación del hecho y se proceda acto seguido a su destrucción. Elsevier España y Elsevier Doyma se reserva el ejercicio de las acciones legales que le correspondan contra quienes accedan de forma ilegítima al contenido de los mensajes remitidos desde cualesquiera sociedades o entidades integradas dentro de su estructura empresarial.

Reply Forward

11. 31 Juni 2020

Gmail

Medicina Clínica Práctica

Compose

Inbox 1,822

Starred

Snoozed

Sent

Drafts 5

More

Labels +

takdirtahir@g.un... 1,167


Article_Status@elsevier.com
to me

Thu, Jun 11, 2020, 5:22 PM

ELSEVIER

Dear Dr. Tahir,

Congratulations on publishing your article *Evaluation of acute wound healing potential of red dragon fruit (*Hylocereus Polyrhizus*) extract cream on type III collagen and Epidermal Growth Factor (EGF) levels: an animal study* in **Medicina Clínica Práctica**. Thank you for your contribution to the journal and we hope you will consider submitting an article to an Elsevier-published journal again in the future.



As a commitment to improving our service to authors, we would like to invite you to participate in our Author Feedback Program. You will receive an e-mail invitation to complete an online questionnaire from Elsevier, asking you to evaluate our performance. Your opinion is very important to us and will enable us to monitor and improve our services for authors.

Please note: you will not be sent a questionnaire if you have received an author feedback questionnaire from us within the last 6 months or have previously informed us that you do not wish to receive a survey.

Thank you for your cooperation.

Yours sincerely,
Elsevier Researcher Support